

January 23 rd , 2023	Original	1

c Queen's University

L c cc Principal Investigators, Research Staff, Veterinary Staff

The purpose of this Standard Operating Procedure (SOP) is to describe the technique for performing an ovariectomy using the dorsal approach in the rat.

Ovariectomy (surgical removal of the ovaries) is a common procedure in rodents. The single incision dorsal approach is the least invasive method used.

Animal Care Services, Principal Investigator subcutaneous, intravenous, intraperitoneal intramuscular, per os per rectum

Anesthetics (refer to SOP 10.6)

Gas anesthesia machine (calibrated within the last 12 months and with active or passive scavenging)

Transparent induction chamber

Nose cone

Analgesics (refer to SOP 10.1)

PPE (cap, gloves, mask, clean lab coat or surgical gown)

Standard surgical gloves

Clippers

Scale

Eye lubricant and sterile cotton tip applicator

Heat lamp

Lactated Ringers solution (fluid therapy)

Surgical scrub

January 23 rd , 2023	Original	2

Suture material

Preparation for Surgery:

Blood collection performed prior to the surgery for measuring hormone concentration, if required as per protocol.

Analgesics may be given preoperatively as per protocol. Refer to SOP 10.1 "Pain Management (Rat)"

Anesthetize and prep rat as per SOP 10.3 "Aseptic Surgical Techniques (Rat)"

Place the rat on the prep area in sternal recumbency.

Shave an area on the rat bounded dorsally by the spine, laterally from the last rib to the hindleg and ventrally to the sides of the rat. Shave both sides of the rat (Figure 1).

Surgical Procedure using a Single Dorsal Incision:

Place a sterile drape over the rat with the opening situated over the surgery site.

A dorsal skin incision is made parallel and lateral to the spine from the mid-thoracic curvature to end of curvature (Figure 2). The skin incision can then be shifted to either side of the abdomen until a white patch becomes visible in the area under the skin. The white patch

January 23 rd , 2023	Original	3

The hemostats should be left clamped for 15-20 seconds to minimize hemorrhage. Gently holding the fat pad, release the hemostats and check for bleeding. If

January 23 rd , 2023	Original	4

Figure 2 – Skin Incision

Figure 3 – Shifting skin to lateral aspect of the thorax to find white patch

January 23 rd , 2023	Original	5



Figure 4 - Incision through muscle wall to expose fat pad, single suture on muscle wall

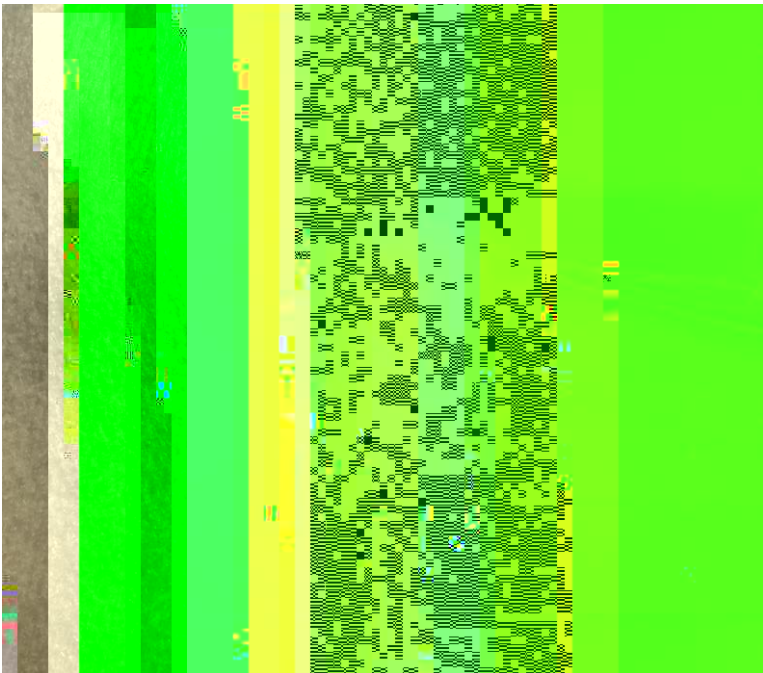


Figure 5 - Fat pad gently lifted outwards to exteriorize the ovary

January 23 rd , 2023	Original	8

L

M L c c c

Date	New Version
